

# Endoluminal fundoplication by a transoral device for the treatment of GERD: A feasibility study

G. B. Cadière · A. Rajan · O. Germay ·  
J. Himpens

Received: 13 April 2007 / Accepted: 29 August 2007  
© Springer Science+Business Media, LLC 2007

## Abstract

**Background** A new endoluminal fundoplication (ELF) technique performed transorally using the EsophyX™ device was evaluated for the treatment of gastroesophageal reflux disease (GERD) in a prospective, feasibility clinical trial.

**Methods** Nineteen patients were enrolled into the study. Inclusion criteria were chronic and symptomatic GERD, proton pump inhibitor (PPI) dependence, and the absence of esophageal motility disorder. Two patients were excluded due to esophageal stricture and a 6 cm hiatal hernia. The median duration of GERD symptoms and PPI use in the remaining 17 patients was 10 and 6 years, respectively. The ELF procedure was designed to partially reconstruct the antireflux barrier through the creation of a valve at the gastroesophageal junction.

**Results** The ELF-created valves had a median length of 4 cm (range 3–5 cm) and circumference of 210° (180–270°). Adherence of the valves to the endoscope was tight ( $n = 14$ ) or moderate ( $n = 3$ ). Hiatal hernias present in 13 patients (76%) were all reduced. Adverse events were limited to

mild or moderate pharyngeal irritation and epigastric pain, which resolved spontaneously. After 12 months, the ELF valves ( $n = 16$ ) had a median length of 3 cm (1–4 cm) and a circumference of 200° (150–210°). Eighty-one percent of valves retained their tightness. The hiatal hernias present at the baseline remained reduced in 62% of patients. The median GERD-HRQL scores improved by 67% (17–6), and nine patients (53%) improved their scores by  $\geq 50\%$ . Eighty-two percent of patients were satisfied with the outcome of the procedure, 82% remained completely off PPIs, and 63% had normal pH.

**Conclusion** The study demonstrated technical feasibility and safety of the ELF procedure using the EsophyX™ device. The study also demonstrated maintenance of the anatomical integrity of the ELF valves for 12 months and provided preliminary data on ELF efficacy in reducing the symptoms and medication use associated with GERD.

**Keywords** Antireflux barrier · EsophyX · ELF procedure · Heartburn · Hiatal hernia · Quality of life · Reflux

---

G. B. Cadière (✉) · O. Germay  
Centre Hospitalier, Universitaire St. Pierre, 322, rue Haute,  
Brussels 1000, Belgium  
e-mail: guy\_cadiere@stpierre-bru.be

A. Rajan  
Clinique du Parc Léopold, Centre Hospitalier Interrégional Edith  
Cavell (CHIREC), Brussels, Belgium

J. Himpens  
Sint Blasius Hospital, Dendermonde, Belgium

Chronic gastroesophageal reflux disease (GERD) symptoms affect 10% of population of Western Europe and the United States on a daily basis and 25–40% of population at least once a month [1–4]. Medical therapy using proton pump inhibitors (PPIs) results in a significant symptom control. It does not address, however, the root cause of the disease nor treat volume reflux and regurgitation [5].

Surgical approaches to the treatment of GERD have proven to be an effective alternative to lifelong medication use and lifestyle changes. The underlying rationale for the surgical treatment of GERD is to repair the natural

anatomy of the gastroesophageal junction (GEJ), in particular the antireflux barrier (ARB), through restoration of a gastroesophageal valve (GEV), the angle of His, and the high pressure zone of the ARB, all of which deteriorate over the course of the disease.

Following the development of open surgical fundoplication in the 1950s [6], new less invasive surgical approaches to this disease have been pursued. Laparoscopic Nissen fundoplication (LNF), which was conceived and perfected in the 1990s [7–10], represents the gold-standard surgical treatment for GERD because of its ability to restore the ARB's competency through recreation of the angle of His, elevation of resting pressure at the lower esophageal sphincter (LES), and concomitant reconstruction of the GEV at the GEJ. Despite proven long-term effectiveness of LNF, gastroenterologists and primary care physicians are frequently reluctant to refer patients because of the variability of surgeon-dependent results, continued (albeit reduced) invasiveness, and frequent side effects including gas bloat, diarrhea, and dysphagia, which may be difficult to treat [10, 11]. The latter symptoms are due to the extent of the dissection of GEJ region with severance of all ligaments that fix the GEJ, the crural repair, and the surgically-created posterior wrap.

Transoral endoluminal techniques have remained the most promising alternatives. Following the pioneering attempts by Donahue in 1980 to achieve endoscopic sclerosis of the cardia [12], several endoscopic procedures aiming at improvement of the barrier function of the lower esophageal sphincter (LES) have emerged [13–15]. Initial attempts involved narrowing of the LES either by suturing, radiofrequency [16–21], or injection of a foreign material [22–25]. However, none of these techniques have been shown to be effective and most of them have been withdrawn from the market [14, 26, 27].

An endoscopic technique that attempts to mimic the effects of antireflux surgery by recreating the ARB, reducing hiatal hernia, restoring the angle of His, and forming a one-way GEV would appear to be most effective in the treatment of GERD [28]. The technique utilizing the Plicator device (NDO Surgical, Inc., Mansfield, MA) moves in this general direction [29, 30], and the first randomized sham study shows promising subjective and objective results [31]. However, repeated reinsertion and removal of the device in order to place more than one stitch is a limitation [29]. Furthermore, the effectiveness of the Plicator in treating GERD appears compromised by its inability to reduce hiatal hernia and create a robust GEV.

With the novel endoluminal fundoplication (ELF) technique described in this study, the GEV is created from the inside of the stomach via transoral access rather than through the peritoneal cavity as in surgical fundoplication.

The ELF technique consists of inserting the EsophyX™ device (EndoGastric Solutions, Inc., Redmond, WA, USA) transorally with the goal of creating a full-thickness omega-shaped valve 3–5 cm in length and 200–300° in circumference through delivery of multiple fasteners under direct endoscopic visualization. In animal studies, histological analysis of ELF-created valves revealed serosal fusion at 4 weeks [32]. The purpose of this prospective clinical trial was to evaluate the technical feasibility, safety, and preliminary efficacy of the ELF procedure in patients with chronic GERD symptoms who were dissatisfied with long-term PPI use and referred for Nissen fundoplication. This paper reports on 1-year follow-up results.

## Patients and methods

The study protocol was approved by the ethics committee at the Centre Hospitalier Universitaire St. Pierre, and patients referred for laparoscopic Nissen fundoplication between June and October 2005 were offered the ELF procedure. A subset of patients agreed to undergo ELF after informed consent that included a description of alternative surgical and laparoscopic treatments. The study was designed as a prospective, single-center feasibility trial and was intended to include 15–20 patients.

The inclusion criteria were chronic symptomatic GERD lasting more than 6 months, esophagitis grade A–C according to the Los Angeles classification [33], chronic PPI dependence for more than 6 months with recurrence of symptoms upon PPI treatment cessation, deteriorated or absent GEV, and the absence of significant esophageal motility disorder or other esophageal pathology. The exclusion criteria were similar to those for Nissen fundoplication including dysphagia, with the addition of BMI  $\geq 30$  kg/m<sup>2</sup>, irreducible hiatal hernia larger than 3 cm, esophageal stricture, Barrett's esophagus, esophageal ulcer, delayed gastric emptying, and previously failed antireflux procedures.

Preprocedure evaluation included flexible upper GI endoscopy, 24-hour ambulatory pH, manometry, a nine-item GERD health-related quality-of-life (GERD-HRQL) questionnaire [34], barium swallow radiography, and medication history. The protocol stipulated discontinuation of PPIs for a minimum of 7 days prior to completion of GERD-HRQL and pH assessment at baseline. Postoperative follow-up performed at 3, 6, and 12 months included upper GI endoscopy, 24-hour ambulatory pH, the GERD-HRQL questionnaire, and details on GERD medication usage. In addition, the patients were asked by the study coordinator whether they were “very satisfied”, “satisfied”, “neutral”, “unsatisfied” or “very unsatisfied” with

the ELF procedure in order to determine a satisfaction index at 12 months.

Upper GI endoscopy was performed before and after the procedure to grade esophagitis and to exclude Barrett's esophagus. A hiatal hernia was diagnosed when the Z-line was above the diaphragmatic pinch caused by external compression by the crus or when a herniation was visible on the retroflexed endoscopic view. A qualitative assessment of the anatomical aspects of the ELF-created GEV was performed by reviewing endoscopic recordings. Hill grade [35], adherence to scope, valve circumference [36], and the angle of His [37] were evaluated.

Preoperative 24-hour pH assessment of esophageal pH was performed using an antimony pH-catheter (Medtronic, Minneapolis, MN, USA) and a Mark III Digitrapper<sup>TM</sup> (Medtronic). A wireless Bravo<sup>TM</sup> pH monitoring system (Medtronic) was used for the postoperative 48-hour assessment. The percentage of the time at pH <4 was used for detecting acid reflux. A normal esophageal acid exposure was determined when the percentage of the time at pH <4 was  $\leq 4.1\%$  for Digitrapper values and  $\leq 5.3\%$  for Bravo values [38–40].

#### The ELF procedure

The ELF technique using the EsophyX<sup>TM</sup> device (Fig. 1) was designed to recreate full-thickness GEVs (Fig. 2), which are similar to those resulting from surgical fundoplication. The ELF-created GEV included two layers of gastric wall and extended over a length of a 3–5 cm and a circumference of 200–300° [41].

The ELF technique was performed under general anesthesia by a team consisting of a surgeon and a gastroenterologist. The surgeon operated the device while the gastroenterologist operated the endoscope to ensure proper exposure and continuous visualization throughout the entire procedure. Each patient was positioned on the left side (left lateral decubitus position). The disposable EsophyX<sup>TM</sup> device, which rides axially over a standard endoscope (Olympus GIF 160), and the endoscope were



**Fig. 1** The distal molding part of the EsophyX<sup>TM</sup> device

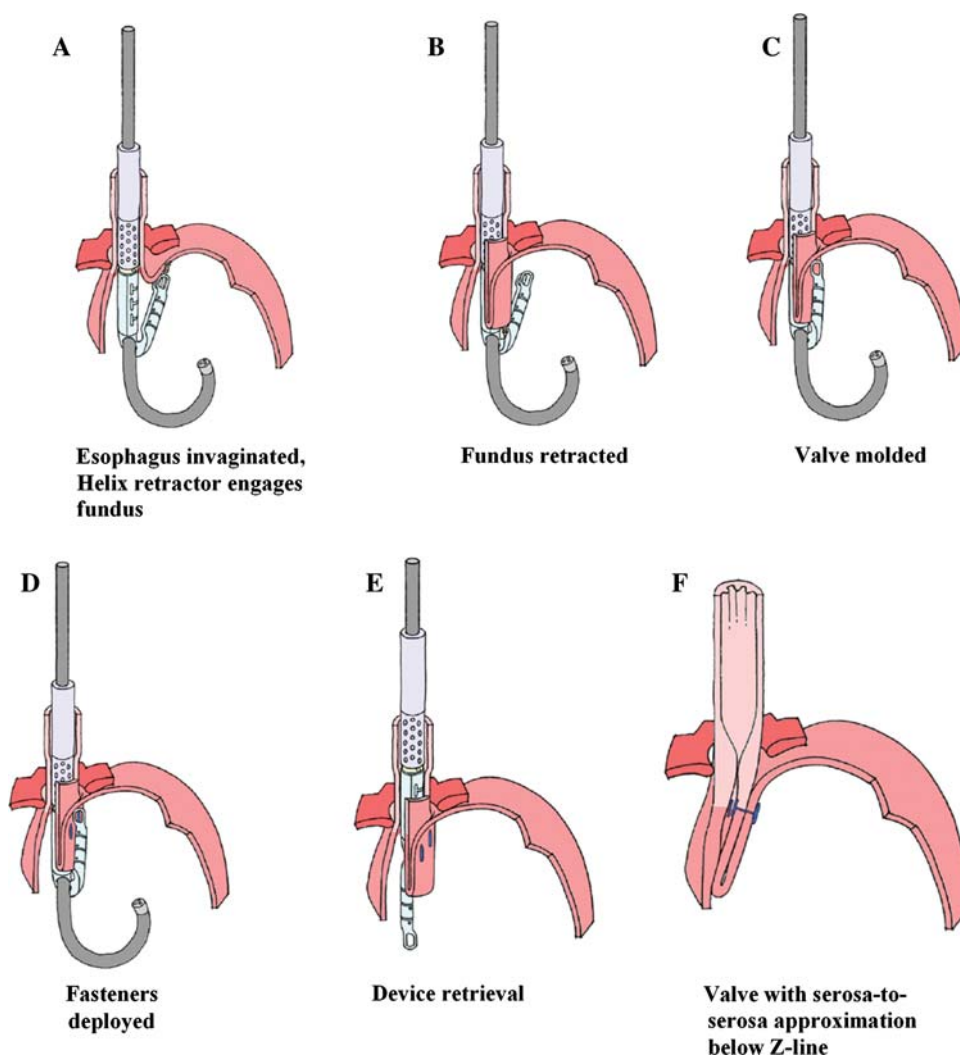
passed transorally through the esophagus into the stomach. A proprietary invaginator incorporated into the device was used to engage the distal esophagus and reduce hiatal hernia, if present, by advancing aborally the device inside of the esophagus. Gastric tissue from the fundus was drawn between the body of the device, and a tissue mold was used to create each portion of the revised GEV (Fig. 2). Proprietary polypropylene fasteners were delivered across the molded tissue to create a 3–5 cm long plication [32]. The fastener deployment process started at the greater curvature and continued toward the lesser curve in order to create an omega-shaped valve with 200–300° of circumference (Fig. 3). After withdrawal of the device, endoscopy was repeated to evaluate the length and circumference of the newly created valve and to inspect the structural integrity of the esophagus and stomach. The circumference was assessed from the greatest radius between the two most distant fasteners from the valve center.

Each patient was admitted overnight and discharged on the following day after a careful clinical examination. Patients were instructed to stop PPIs 7 days after the procedure and to contact the study investigator immediately in case of any complications or adverse events. Follow-up consisted of a telephone call from the study coordinator at postoperative weeks 1 and 2 and an outpatient assessment at 3, 6, and 12 months as defined by the study protocol.

#### Statistical analysis

The primary study endpoint was an improvement of  $\geq 50\%$  in the GERD-HRQL score at 12 months post-procedure compared to those at baseline. Patients achieving  $\geq 50\%$  improvement in GERD-HRQL scores at 12 months compared to baseline were considered responsive to the ELF procedure. Patients who failed to reach this level of improvement were considered poor responders to the ELF procedure. Continuous variables such as age, procedure duration, percentage of time at pH <4, and GERD-HRQL score were summarized by mean and standard deviation or median and range. Improvement in the percentage of time at pH <4 and a reduction in the use of PPIs were analyzed as secondary endpoints, with treatment success defined by an acid exposure equal to or less than 5.3% of time at pH <4 and by elimination of PPI therapy. Categorical variables, such as PPI use and satisfaction level, were summarized as counts and percentages. Because of non-symmetric data distributions, *P* values for changes from baseline to 12 months for GERD-HRQL score and percentage of time at pH <4 were calculated using the Sign test (SAS 9.1, Cary, NC, USA). Values with *P* <0.05 were considered significant.

**Fig. 2** Schematic drawings illustrating the ELF technique using the EsophyX™ device



## Results

### Patient characteristics

Nineteen patients were initially enrolled into the study. Two patients were excluded. The first was not treated due to a moderate preexisting esophageal stenosis that precluded safe device introduction, and the second was discovered preoperatively to have a 6 cm hiatal hernia. This patient was treated outside of the study protocol and later received a laparoscopic Nissen fundoplication. This patient's results were not included in the study.

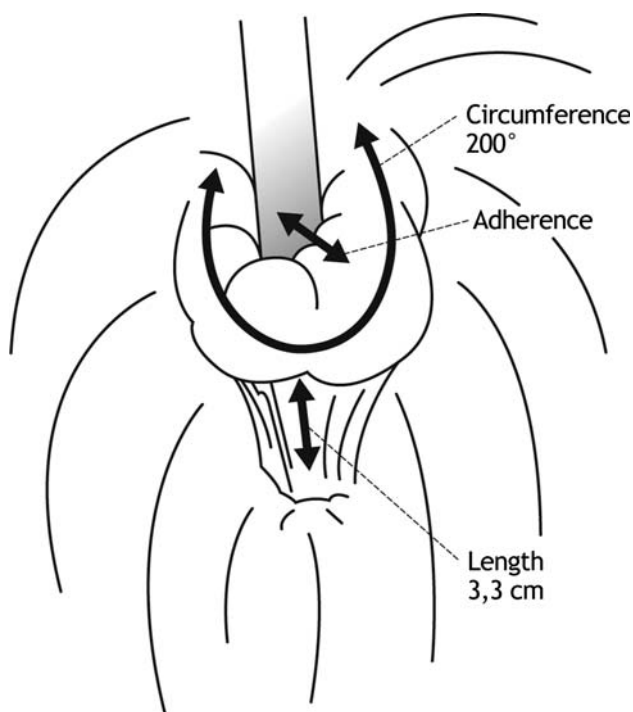
The remaining 17 patients (7 males and 10 females) had a median age of 34 years (range 23–58 years) and a median BMI of 22 kg/m<sup>2</sup> (18–31 kg/m<sup>2</sup>). All patients suffered from GERD for a median of 10 years (3–15 years) and were on continuous daily PPI medication for a median of 6 years (2–13 years). All 17 patients suffered from typical heartburn and 13 suffered from regurgitation. All patients had

documented recurrence of GERD symptoms upon PPI discontinuation and, as a result, were unwilling to comply with the protocol requirement of discontinuing the PPI use for the full 7 days. Median GERD-HRQL score was 17 at baseline (12–31).

Upper GI endoscopy showed evidence of reflux esophagitis in all patients at screening (grade A:  $n = 13$  (76%); grade B:  $n = 2$  (12%); and grade C:  $n = 2$  (12%) in the Los Angeles classification, [33]). The natural GEVs appeared loose around the endoscope in all cases (Fig. 4). A reducible hiatal hernia (median size 2 cm, range 1–3 cm) was seen in 13 (76%) patients.

### The ELF procedure: Technical feasibility and safety

The median procedure time was 123 min (range 55–254 min) and decreased progressively from 132 min (88–254 min) for the first seven patients to 119 min (55–219 min)



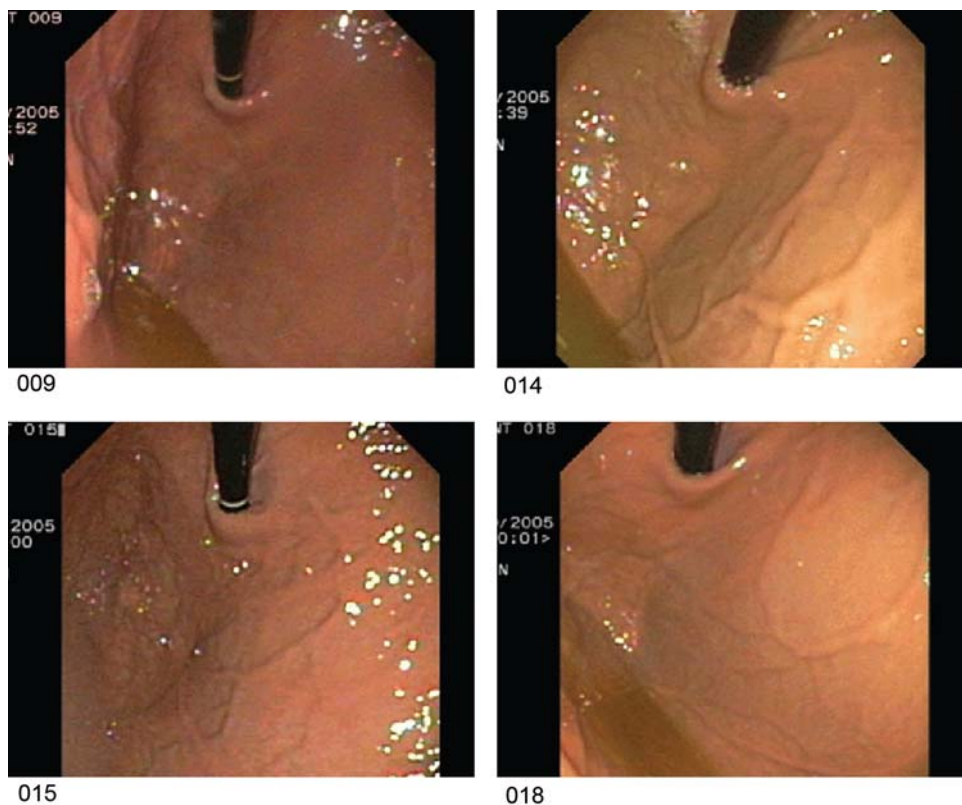
**Fig. 3** Schematic drawing of an ELF-created gastroesophageal valve and its anatomical aspects

for the last 10 patients. A learning curve was observed along with improvements in device performance. The median number of devices used per patient was one (1–4)

and decreased from two for the first seven patients (1–4) to one for the last 10 patients. More than two devices were introduced only in one patient. The median number of fasteners placed per patient was 11 (6–14). The median length and circumference of the ELF-created GEVs immediately postoperatively were 4 cm (3–5 cm) and 210° (180–270°), respectively. The number of valves assessed as being tight, moderate, and loose around the endoscope was 14, 3, and 0, respectively. All hiatal hernias were completely reduced.

There were no serious immediate perioperative complications such as perforation, bleeding or death. All 17 patients were discharged the day after the procedure. On the first day after the procedure, 11 (65%) patients reported pharyngeal irritation as a result of the device insertion and manipulation, but none of them complained of dysphagia (Table 1). All patients experienced mild epigastric pain that was treated with analgesics and resolved within 1 week. One patient had transient dysphonia. One patient was readmitted in the first postprocedure week. This patient was treated with analgesics and a prophylactic course of antibiotics for 3 days. Blood chemistry and hematology were within normal limits. A thoracic and abdominal computed tomography (CT) scan showed air in the upper abdomen. Perforation was ruled out by gastrografin swallow and no intervention was required. The patient was discharged with no further sequelae throughout the

**Fig. 4** Gastroesophageal valves before ELF



remaining 1-year follow-up period. It was concluded that the intra-abdominal air resulted from the lengthy therapeutic endoscopic procedure.

**Table 1** Adverse events

	Day 1	Week 1	Week 2
Bloating	10 (59%)	7 (41%)	3 (18%)
Diarrhea	6 (35%)	1 (6%)	0 (0%)
Difficulty swallowing	3 (18%)	3 (18%)	2 (12%)
Dysphagia	0 (0%)	0 (0%)	0 (0%)
Epigastric pain	17 (100%)	1 (6%)	1 (6%)
Eructation	4 (24%)	7 (41%)	6 (35%)
Fever	2 (12%)	0 (0%)	0 (0%)
Flatulence	1 (6%)	1 (6%)	1 (6%)
Globus	0 (0%)	0 (0%)	0 (0%)
Hematemesis	1 (6%)	1 (6%)	0 (0%)
Left shoulder pain	7 (41%)	0 (0%)	0 (0%)
Nausea	8 (53%)	3 (18%)	0 (%)
Pharynx irritation	11 (65%)	6 (35%)	3 (18%)
Vomiting	1 (6%)	0 (0%)	1 (6%)

Patient follow-up at 12 months

All patients (100%) completed the GERD-HRQL assessment and 16 of the 17 patients (94%) completed the endoscopy examination and 48-hr pH assessment. At the follow-up visit, all patients on PPIs discontinued their medication for 15 days prior to the assessment.

Median GERD-HRQL scores (Table 2) improved significantly ( $P = 0.02$ ) by 67% from 17 at baseline on PPIs to 6. An improvement in the GERD-HRQL score of  $\geq 50\%$  was demonstrated in 53% (9/17) of patients. Based on the satisfaction index, 82% of patients were satisfied or very satisfied with the outcome of the ELF procedure.

The use of PPIs was completely discontinued in 82% (14/17) of patients, and 63% (10/16) of patients had normal esophageal acid exposure (Table 2) at 12 months post-procedure.

Qualitative upper GI endoscopic evaluation conducted in 16 patients revealed that 81% (13/16) of the ELF-created valves maintained their tightness at 12 months postprocedure (Table 3, Fig. 5). The median circumference of the valves was 200° (150–210°), and the median length was 3 cm (1–4 cm). Hiatal hernias remained reduced in 62% (8/

**Table 2** GERD-HRQL score improvement, esophageal acid exposure based on 48-hour pH monitoring, proton pump inhibitor (PPI) use and satisfaction index at 12 months after the ELF procedure

Patient ID	GERD-HRQL Score Improvement (baseline versus 12 months) (%)	48-hr pH monitoring			PPI use	Satisfaction index
		DeMeester score	Time at pH <4 (%)	Normal pH <sup>1</sup>		
001	-11 (19–21)	23.1	7.8	No	Yes	Very unsatisfied
002	47 (15–8)	3.1	0.8	Yes	None	Satisfied
003	18 (17–14)	30.4	11.6	No	Yes	Very unsatisfied
004	100 (16–0)	10.7	3.7	Yes	None	Very satisfied
005	-21 (14–17)	13.4	5.1	Yes	None	Very satisfied
006	94 (16–1)	17.1	5.3	Yes	None	Very satisfied
007	-19 (21–25)	7.4	1.6	Yes	None	Satisfied
008	71 (14–4)	ND	ND	ND	None	Satisfied
009	75 (12–3)	20.9	7.0	No	None	Very satisfied
010	48 (23–12)	10.3	2.9	Yes	None	Satisfied
012	44 (16–9)	21.1	7.6	No	None	Satisfied
013	85 (27–4)	7.1	1.6	Yes	None	Very satisfied
014	76 (17–4)	1.5	0.3	Yes	None	Very satisfied
015	76 (25–6)	13.5	4.2	Yes	None	Very satisfied
016	86 (21–3)	2.6	0.6	Yes	None	Very satisfied
017	16 (31–26)	18.8	6.4	No	Yes	Unsatisfied
018	67 (15–5)	21.3	7.2	No	None	Very satisfied
N	17	16	16	16	17	17
Median	67 (17–6)	13.5	4.7	10/16 Yes (63%)	14/17 None (82%)	14/17 Very satisfied (82%)

<sup>1</sup> Normal pH defined as percentage time at pH < 4 for less than or equal 5.3% of time

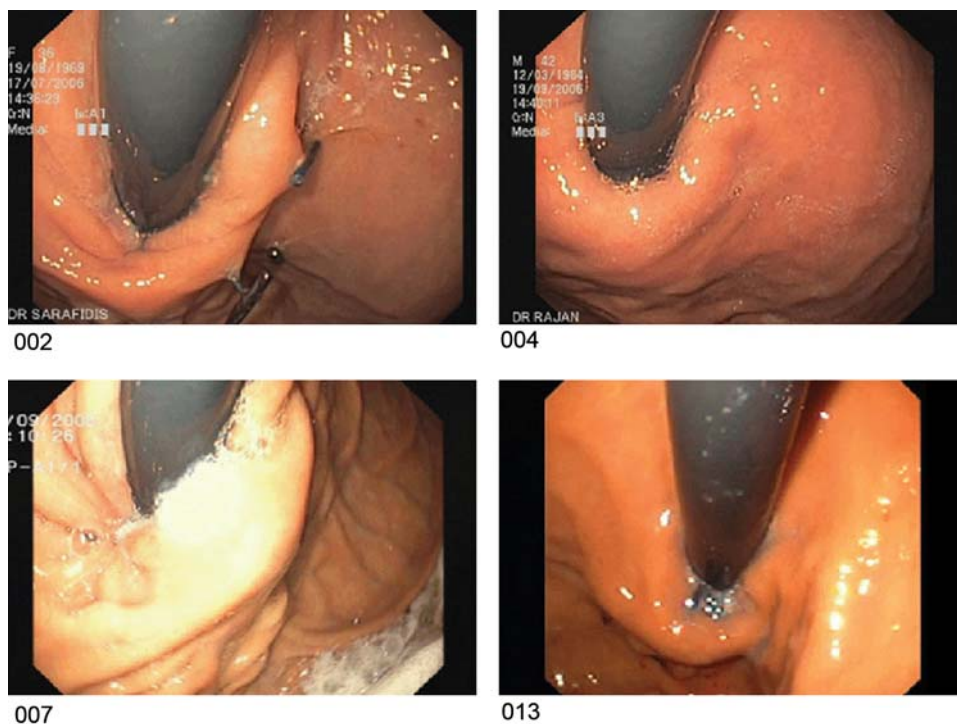
ND: not determined

**Table 3** Hiatal hernia (HH), esophagitis grade and the ELF valve aspects evaluated by endoscopy

Patient ID	HH size (cm)		Esophagitis grade		Qualitative valve aspects				Adherence to scope	
	Baseline	12 months	Baseline	12 months	Jobe length (cm)		Circumference (°)		Immediately postoperatively	12 months
					Immediately postoperatively	12 months	Immediately postoperatively	12 months		
001	2	0	A	A	ND	3.5	180	180	T	M
002	2	0	A	A	ND	3.5	250	200	T	T
003	2	0	B	A	ND	3.0	200	210	T	L
004	0	0	C	A	ND	4.0	260	210	T	M
005	3	0	C	A	ND	3.0	210	210	T	M
006	0	0	A	None	ND	3.0	180	210	T	M
007	2	1.5	A	A	3.0	2.0	270	180	T	M
008	2.5	ND	A	ND	3.0	ND	270	ND	T	ND
009	2	0	A	B	4.0	2.5	180	200	M	M
010	2	2	A	A	4.0	2.0	270	150	T	L
012	2	0	A	None	4.0	3.5	210	180	T	L
013	2	2	A	A	4.0	3.5	230	210	M	M
014	0	0	A	A	4.0	2.5	180	180	M	M
015	3	2	A	B	4.5	3.0	195	210	T	M
016	0	0	A	None	5.0	2.5	210	180	T	M
017	2.5	2	B	B	4.0	1.0	210	180	T	M
018	2	0	A	A	5.0	2.5	240	210	T	M
N	17	16	17	16	11	16	17	16	17	16
Median (Range)	2 (0–3)	0 (0–2)	–	3 None (19%)	4 (3–5)	3 (1–4)	210 (180–270)	200 (150–210)	14 T (82%)	1 T (6%)
			13 A (76%)	10 A (62%)					3 M (18%)	12 M (75%)
			2 B (12%)	3 B (19%)					0 L (0%)	3 L (19%)
			2 C (12%)	0 C (0%)						

L, loose; M, moderate; ND, not determined; T, tight

**Fig. 5** ELF-created gastroesophageal valves at 12 months



13) of patients (Table 3). Grade A or B esophagitis was observed in 13 patients. None of the patients had grade C esophagitis.

## Discussion

The present study represents the first clinical evaluation of the ELF procedure using the EsophyX™ device and demonstrated its technical feasibility and safety. The pre-operative assessment of esophageal pH and GERD-HRQL scores could not be completed while off PPIs in many of the patients due to patient refusal to discontinue PPI use for 7 days before the assessment. The severity of GERD in all 17 patients was confirmed by the existence of esophagitis and the median duration of symptoms and PPI use of 10 and 6 years, respectively. Although the initial results of the study support the ability of the ELF procedure to reduce the symptoms associated with GERD and to reduce the use of PPIs, definitive conclusions regarding the effectiveness of the ELF procedure in terms of normalization of pH cannot be drawn.

Potential advantages of the ELF technique using the EsophyX™ device compared with LNF include the absence of abdominal incisions, reduced invasiveness resulting in reduced pain, faster postprocedure recovery, and absence of dysphagia, diarrhea, and gas bloat syndrome. All patients treated with the ELF technique were discharged from the hospital on the first postoperative day. The absence of complications typical for antireflux surgery

following the ELF procedure may be associated with the absence of dissection of all gastroesophageal attachments and absence of a wrap completely encircling the esophagus. Future work is expected to demonstrate that the new ELF technique may also be revised or adjusted with the transoral delivery of additional fasteners. This would represent an advantage in comparison to the challenges and risks of redoing a Nissen fundoplication.

The ELF technique using the EsophyX™ device appeared capable of creating a robust valve with a length of 4 cm and a circumference of 210°, which was similar to the valve created by LNF. After 12 months, the anatomical deterioration of the newly-created valves was minimal and good functional results were maintained. The median duration of the procedure was reduced with increased investigator's experience. As a result of this learning curve, the procedure duration for the last 10 patients was reduced by 10% compared to the first eight patients and was only slightly longer than a typical LNF. The high level of coordination required between the two operators may explain the prolonged learning curve associated with the procedure. A technical mastery and enhanced team coordination should lead to further reduction in the duration of the procedure.

In conclusion, the results from the present study demonstrate the technical feasibility and safety of the new ELF procedure using the EsophyX™ device. This new technique resulted in the creation of robust and durable GEVs that improved the functionality of the ARB. A multicenter study is currently underway to evaluate the long-term efficacy of the ELF procedure.

**Disclosure** The study was sponsored by EndoGastric Solutions, Inc., Redmond, WA, USA.

## References

- Fass R, Ofman JJ (2002) Gastroesophageal reflux disease—should we adopt a new conceptual framework? *Am J Gastroenterol* 97:1901–1909
- Howard PJ, Heading RC (1992) Epidemiology of gastro-esophageal reflux disease. *World J Surg* 16:288–293
- Moayyedi P, Talley NJ (2006) Gastro-oesophageal reflux disease. *Lancet* 367:2086–2100
- Pace F, Bollani S, Molteni P, Bianchi Porro G (2004) Natural history of gastro-oesophageal reflux disease without oesophagitis (NERD)—a reappraisal 10 years on. *Dig Liver Dis* 36:111–115
- Koop H (2006) Medical therapy of gastro-oesophageal reflux disease. In: Granderath FA, Kamolz T, Pointner R (eds). *Gastroesophageal Reflux Disease: Principles of Disease, Diagnosis, and Treatment*. Springer, Wien, New York, pp 103–111
- DeMeester TR, Bonavina L, Albertucci M (1986) Nissen fundoplication for gastroesophageal reflux disease. Evaluation of primary repair in 100 consecutive patients. *Ann Surg* 204:9–20
- Cadiere GB, Houben JJ, Bruyns J, Himpens J, Panzer JM, Gelin M (1994) Laparoscopic Nissen fundoplication: Technique and preliminary results. *Br J Surg* 81:400–403
- Hinder RA, Filipi CJ, Wetscher G, Neary P, DeMeester TR, Perdakis G (1994) Laparoscopic Nissen fundoplication is an effective treatment for gastroesophageal reflux disease. *Ann Surg* 220:472–481
- Weerts JM, Dallemagne B, Hamoir E, Demarche M, Markiewicz S, Jehaes C, Lombard R, Demoulin JC, Etienne M, Ferron PE, et al. (1993) Laparoscopic Nissen fundoplication: detailed analysis of 132 patients. *Surg Laparosc Endosc* 3:359–364
- Dallemagne B, Weerts J, Markiewicz S, Dewandre JM, Wahlen C, Monami B, Jehaes C (2006) Clinical results of laparoscopic fundoplication at ten years after surgery. *Surg Endosc* 20:159–165
- Peters JH, DeMeester TR, Crookes P, Oberg S, de Vos Shoop M, Hagen JA, Bremner CG (1998) The treatment of gastroesophageal reflux disease with laparoscopic Nissen fundoplication: Prospective evaluation of 100 patients with “typical” symptoms. *Ann Surg* 228:40–50
- Donahue PE, Carvalho PJ, Davis PE, Shen YJ, Miidla I, Bombeck CT, Nyhus LM (1990) Endoscopic sclerosis of the gastric cardia for prevention of experimental gastroesophageal reflux. *Gastrointest Endosc* 36:253–256
- Arts J, Tack J, Galmiche JP (2004) Recent advances in clinical practice: Endoscopic antireflux procedures. *Gut* 53:1207–1214
- Hogan WJ (2006) Clinical trials evaluating endoscopic GERD treatments. Is it time for a moratorium on the clinical use of these procedures? *Am J Gastroenterol* 101:437–439
- Iqbal A, Salinas V, Filipi CJ (2006) Endoscopic therapies of gastroesophageal reflux disease. *World J Gastroenterol* 12:2641–2655
- Cipolletta L, Rotondano G, Dughera L, Repici A, Bianco MA, De Angelis C, Vingiani AM, Battaglia E (2005) Delivery of radiofrequency energy to the gastroesophageal junction (Stretta procedure) for the treatment of gastroesophageal reflux disease. *Surg Endosc* 19:849–853
- Corley DA, Katz P, Wo JM, Stefan A, Patti M, Rothstein R, Edmundowicz S, Kline M, Mason R, Wolfe MM (2003) Improvement of gastroesophageal reflux symptoms after radiofrequency energy: A randomized, sham-controlled trial. *Gastroenterology* 125:668–676
- Houston H, Khaitan L, Holzman M, Richards WO (2003) First year experience of patients undergoing the Stretta procedure. *Surg Endosc* 17:401–404
- Lutfi RE, Torquati A, Kaiser J, Holzman M, Richards WO (2005) Three years’ experience with the Stretta procedure: Did it really make a difference? *Surg Endosc* 19:289–295
- Triadafilopoulos G, DiBaise JK, Nostrant TT, Stollman NH, Anderson PK, Wolfe MM, Rothstein RI, Wo JM, Corley DA, Patti MG, Antignano LV, Goff JS, Edmundowicz SA, Castell DO, Rabine JC, Kim MS, Utley DS (2002) The Stretta procedure for the treatment of GERD: 6 and 12 month follow-up of the U.S. open label trial. *Gastrointest Endosc* 55:149–156
- Wolfsen HC, Richards WO (2002) The Stretta procedure for the treatment of GERD: a registry of 558 patients. *J Laparoendosc Adv Surg Tech A* 12:395–402
- Cohen LB, Johnson DA, Ganz RA, Aisenberg J, Deviere J, Foley TR, Haber GB, Peters JH, Lehman GA (2005) Enteryx implantation for GERD: expanded multicenter trial results and interim postapproval follow-up to 24 months. *Gastrointest Endosc* 61:650–658
- Deviere J, Costamagna G, Neuhaus H, Voderholzer W, Louis H, Tringali A, Marchese M, Fiedler T, Darb-Esfahani P, Schumacher B (2005) Nonresorbable copolymer implantation for gastroesophageal reflux disease: a randomized sham-controlled multicenter trial. *Gastroenterology* 128:532–540
- Fockens P, Bruno MJ, Gabbriellini A, Odegaard S, Hatlebakk J, Allescher HD, Rosch T, Rhodes M, Bastid C, Rey J, Boyer J, Muehldorffer S, van den Hombergh U, Costamagna G (2004) Endoscopic augmentation of the lower esophageal sphincter for the treatment of gastroesophageal reflux disease: Multicenter study of the Gatekeeper Reflux Repair System. *Endoscopy* 36:682–689
- Johnson DA, Ganz R, Aisenberg J, Cohen LB, Deviere J, Foley TR, Haber GB, Peters JH, Lehman GA (2003) Endoscopic, deep mural implantation of Enteryx for the treatment of GERD: 6-month follow-up of a multicenter trial. *Am J Gastroenterol* 98:250–258
- Falk GW, Fennerty MB, Rothstein RI (2006) AGA Institute medical position statement on the use of endoscopic therapy for gastroesophageal reflux disease. *Gastroenterology* 131:1313–1314
- Annese V, Caletti G, Cipolletta L, Costamagna G, D’Onofrio V, Leandro G, Koch M, Pace F, Penagini R, Repici A, Ricci E, Vigneri S, Zaninotto G (2005) Endoscopic treatment of gastroesophageal reflux disease. *Endoscopy* 37:470–478
- Falk GW, Fennerty MB, Rothstein RI (2006) AGA Institute technical review on the use of endoscopic therapy for gastroesophageal reflux disease. *Gastroenterology* 131:1315–1336
- Pleskow D, Rothstein R, Lo S, Hawes R, Kozarek R, Haber G, Gostout C, Lembo A (2004) Endoscopic full-thickness plication for the treatment of GERD: A multicenter trial. *Gastrointest Endosc* 59:163–171
- Pleskow D, Rothstein R, Lo S, Hawes R, Kozarek R, Haber G, Gostout C, Lembo A (2005) Endoscopic full-thickness plication for the treatment of GERD: 12-month follow-up for the North American open-label trial. *Gastrointest Endosc* 61:643–649
- Rothstein R, Filipi C, Caca K, Pruitt R, Mergener K, Torquati A, Haber G, Chen Y, Chang K, Wong D, Deviere J, Pleskow D, Lightdale C, Ades A, Kozarek R, Richards W, Lembo A (2006) Endoscopic full-thickness plication for the treatment of gastroesophageal reflux disease: a randomized, sham-controlled trial. *Gastroenterology* 131:704–712
- Cadiere GB, Rajan A, Rqibate M, Gernay O, Dapri G, Himpens J, Gawlicka AK (2006) Endoluminal fundoplication (ELF) - evolution of EsophyX, a new surgical device for transoral surgery. *Minim Invasive Ther Allied Technol* 15:348–355

33. Chandrasoma PT, DeMeester TR (2006) The Past, Present, and Future of Columnar-Lined (Barrett) Esophagus (eds). GERD: Reflux to Esophageal Adenocarcinoma. Boston, Elsevier, pp 11–39
34. Velanovich V, Vallance SR, Gusz JR, Tapia FV, Harkabus MA (1996) Quality of life scale for gastroesophageal reflux disease. *J Am Coll Surg* 183:217–224
35. Hill LD, Kozarek RA, Kraemer SJ, Aye RW, Mercer CD, Low DE, Pope CE 2nd (1996) The gastroesophageal flap valve: In vitro and in vivo observations. *Gastrointest Endosc* 44:541–547
36. Jobe BA, Kahrilas PJ, Vernon AH, Sandone C, Gopal DV, Swanstrom LL, Aye RW, Hill LD (2004) Endoscopic appraisal of the gastroesophageal valve after antireflux surgery. *Am J Gastroenterol* 99:233–243
37. Thor KB, Hill LD, Mercer DD, Kozarek RD (1987) Reappraisal of the flap valve mechanism in the gastroesophageal junction. A study of a new valvuloplasty procedure in cadavers. *Acta Chir Scand* 153:25–28
38. Pandolfino JE, Richter JE, Ours T, Guardino JM, Chapman J, Kahrilas PJ (2003) Ambulatory esophageal pH monitoring using a wireless system. *Am J Gastroenterol* 98:740–749
39. Tseng D, Rizvi AZ, Fennerty MB, Jobe BA, Diggs BS, Sheppard BC, Gross SC, Swanstrom LL, White NB, Aye RW, Hunter JG (2005) Forty-eight-hour pH monitoring increases sensitivity in detecting abnormal esophageal acid exposure. *J Gastrointest Surg* 9:1043–1051
40. Tutuian R, Castell DO (2006) Diagnostic procedures in GERD: Principles and values of esophageal manometry and pH-monitoring In: Grandrath FA, Kamolz T, Pointner R (eds). *Gastroesophageal Reflux Disease: Principles of Disease, Diagnosis, and Treatment*. Springer-Verlag, Wien, New York, pp 121–138
41. Cadiere GB, Rajan A, Dapri G, Rqibate M, Germy O, Himpens J (2006) Nouvelle technique du traitement par voie endoscopique du reflux gastro-oesophagien: La fundoplicature endoluminale. *J Coelio-Chirurgie* 57:14–19