

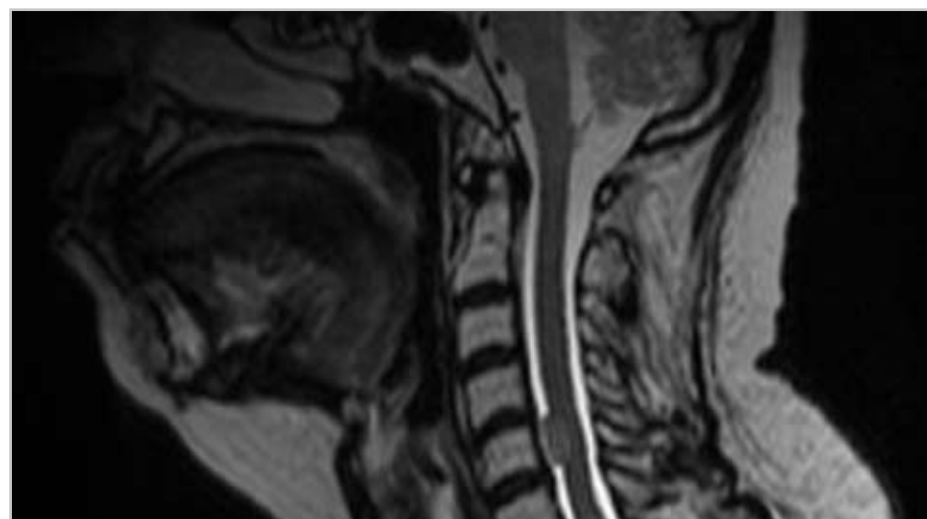
Outcome and Follow-Up:

The patient was seen for multiple follow-up evaluations after completing CyberKnife Stereotactic Radiosurgery.

- One week after therapy the patient was able to stop pain medication.
- Neck pain completely resolved after two weeks and walking improved considerably.
- MRI follow-up scan four weeks after therapy showed tumor shrinkage, with considerable reduction in the spinal cord compression.
- Three months after treatment she continued to be off pain medication and pain free.
- There were no adverse treatment effects during the follow-up period.

Conclusion and CyberKnife Advantages:

Robotic radiosurgery with the Xsight fiducial-less spine tracking system was shown for this patient, to be a safe and effective tool to treat spinal lesions, either as the primary treatment modality or within the framework of a multidisciplinary treatment strategy. This technique might be particularly valuable for recurrent tumors after conventional treatments such as surgery and/or radiation therapy.



T2-weighted MRI scan acquired four weeks post-treatment. There was significant tumor shrinkage. The compression to the spinal cord is considerably reduced.

CYBERKNIFE AT EUROPEAN CYBERKNIFE CENTER, MUNICH (www.cyber-knife.net)

The European Cyberknife Center in Munich is a new medical center operated in collaboration with the University Hospital, Munich. The center is dedicated to providing high precision robotic radiosurgery and is the first Cyberknife facility to open in Germany. The medical team has extensive radiosurgical experience, having previously treated 3200 patients over 12 years. On the basis of this experience they opted to open a new center dedicated to CyberKnife radiosurgery, and in July 2005 the system was installed. By the end of December 2005 approximately 200 patients had been treated for a variety of central nervous system indications, of which approximately 20% have been spinal treatments.

References:

1. Baehring et al. Malignant peripheral nerve sheath tumor: The Clinical Spectrum and Outcome of Treatment. *Neurology*. 61:696-698, 2003
2. Celli P, Trillo G, Ferrante L. Extrathecal Intraradicular Nerve Sheath Tumor. *J Neurosurg Spine*. 3:1-11, 2005
3. Baek WS, Pytel P, Undevia SD, Rubeiz H. Spinal Cord Metastasis of a Non-Neurofibromatosis Type-1 Malignant Peripheral Nerve Sheath Tumor: an Unusual Manifestation of a Rare Tumor. *J Neurooncol*. 74:183-5, 2005
4. Murphy MJ et al. Dosimetric Effect of Intra-fraction Motion During Spinal Radiosurgery *Proceedings – 7th International Stereotactic Radiosurgery Society Congress*, 11-15 Sept 2005, Brussels

C5 MALIGNANT PERIPHERAL NERVE SHEATH TUMOR



European CyberKnife Center (Munich) Team:

Neurosurgeons:	Alexander Muacevic, M.D. Berndt Wowra, M.D.
Medical Physicists:	Christian Drexler, M.Sc. Sibylle Staerk, M.Sc.
Technical Assistant:	Stefanie Himmerich

CyberKnife Center:

European Cyberknife Center
Munich, Germany

C5 MALIGNANT PERIPHERAL NERVE SHEATH TUMOR

DEMOGRAPHICS:

Sex: F
Age: 56
Histology: Malignant peripheral nerve sheath tumor (MPNST)
Treat Date(s): August 2005

CLINICAL HISTORY:

Referred by: Sheba Medical Center, Israel
Previous Treatment: Surgery, Radiotherapy, Chemotherapy.

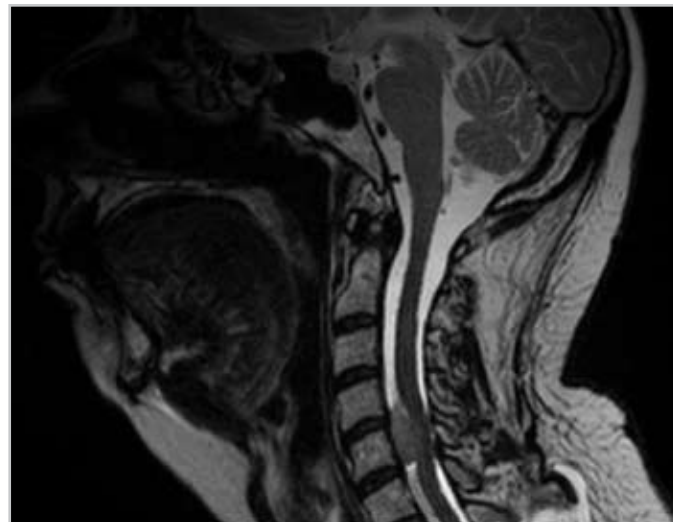
Case History:

Malignant peripheral nerve sheath tumors (MPNST) are rare spindle-cell sarcomas derived from Schwann cells or pluripotent cells of the neural crest. The estimated incidence of MPNST in patients with Neurofibromatosis Type 1 (NF1) is 2-5% compared with 0.001% in the general population. MPNST originate from peripheral nerve root trunks, extremities, and the head and neck region. The tumor can be located intraspinal, foraminal, and extend extraforaminal. These tumors pose specific therapeutic challenges as they recur locally after surgery. Adjuvant conventional radiation therapy improves survival rate or local control in some series but not in others.^{1,2,3}

We present here a rare case of a recurrent spinal non-NF1 MPNST treated by spinal radiosurgery. This 56-year-old female patient was transferred for progressive gait disturbances accompanied by severe neck pain. She was on morphine medication for 8 weeks. Incomplete surgery for a cervical non-NF1 MPNST at the level of C5 was performed 6 months prior to admission. After surgery the patient underwent a course of conventional fractionated radiotherapy (40 Gy) covering the whole spinal canal. Magnetic resonance imaging (MRI) of the cervical spine on admission revealed a large contrast enhancing extradural mass compressing the ventral spinal cord at C5.

CyberKnife Treatment Rationale:

There were no further treatment possibilities as surgery, conventional radiation therapy and chemotherapy were already attempted without preventing tumor growth. It was hoped that additional robotic radiosurgery targeting only the tumor mass could help to prevent further tumor progression and to reduce cervical pain.



T2-weighted pre-treatment MRI scan. The lesion is clearly visualized at C5 significantly compressing the ventral aspect of the cervical spinal cord resulting in severe neck pain.

C5 MALIGNANT PERIPHERAL NERVE SHEATH TUMOR

TREATMENT DETAILS:

Tumor Volume: 1.8 cm³
Imaging Technique(s): CT, MRI
Rx Dose & Isodose: 13.5 Gy to 80%
Conformality Index: 1.46
Tumor Coverage: 91.4%

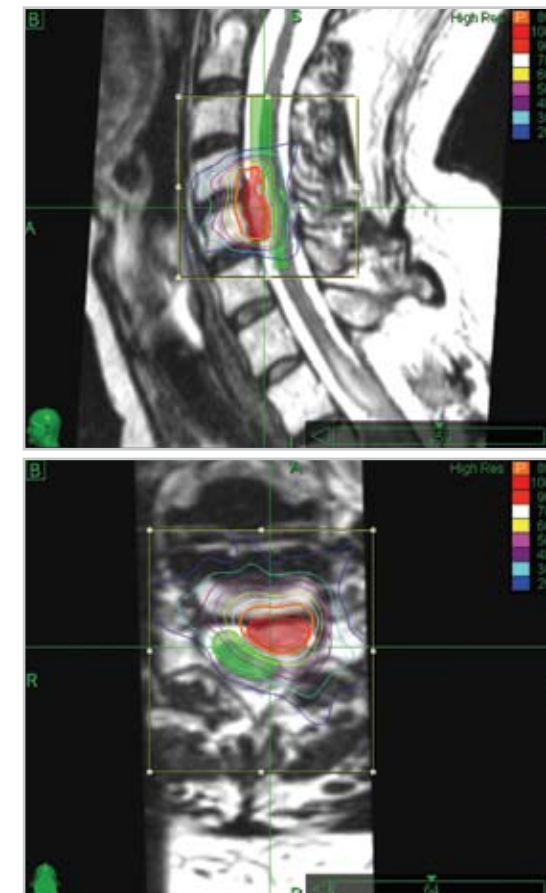
Fractions / Treatment Time: 1 @ 105 minutes
Path Template: 3 paths 900_1000 mm
Tracking Method: Xsight™ spine tracking
Collimator(s): 5 mm
Number of Beams: 311

Treatment Planning Process:

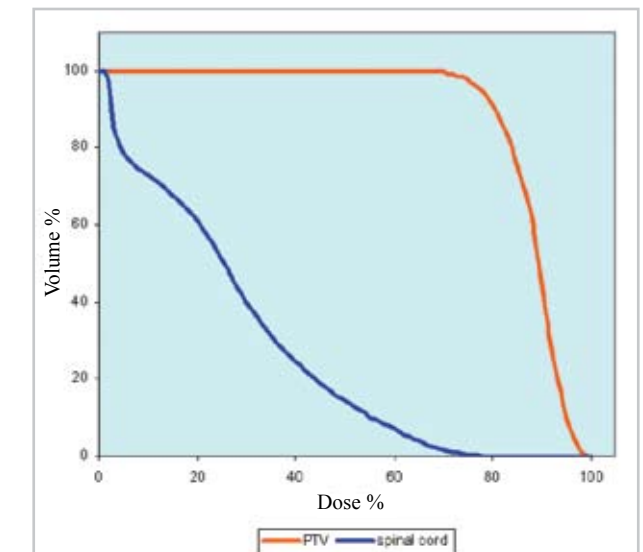
Treatment planning utilized CT, T1- and T2-weighted MRI scans +/- Gd with the patient positioned supine. These data sets were transferred to the MultiPlan treatment planning system and registered using an algorithm based on normalized mutual information. The target volume, spinal cord, and other structures were defined mainly using the T2 MRI data. A treatment plan was generated using an iterative inverse planning algorithm. A dose of 13.5 Gy was prescribed to the 80% isodose, and delivered in a single fraction.

Treatment Delivery:

The patient was treated in August 2005. She was positioned supine and fitted with a thermoplastic mask only. Treatment was delivered using the Xsight™ fiducial-less spine tracking system. With this system the position of the spinal vertebrae are calculated automatically from orthogonal X-ray images acquired during treatment. These are compared with digitally reconstructed radiographs (DRRs) calculated from the pre-treatment CT. The offset required to maintain the alignment of each individual beam to the target volume is calculated by a deformable registration algorithm which also compensates for any non-rigid change in patient position between pre-treatment imaging and treatment delivery. By repeating this process throughout treatment, intra-fraction patient motion, which can be significant in spinal treatments, is effectively negated.⁴



Mid-sagittal (top) and axial (bottom) isodose distributions: The red structure is the target volume and the green structure is the spinal cord. A very steep dose gradient was obtained posteriorly in order to spare the spinal cord.



Dose Volume Histogram (DVH) for all key structures.