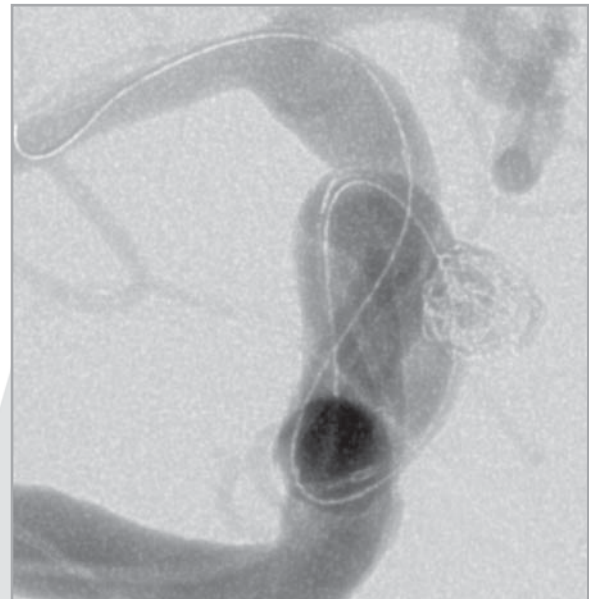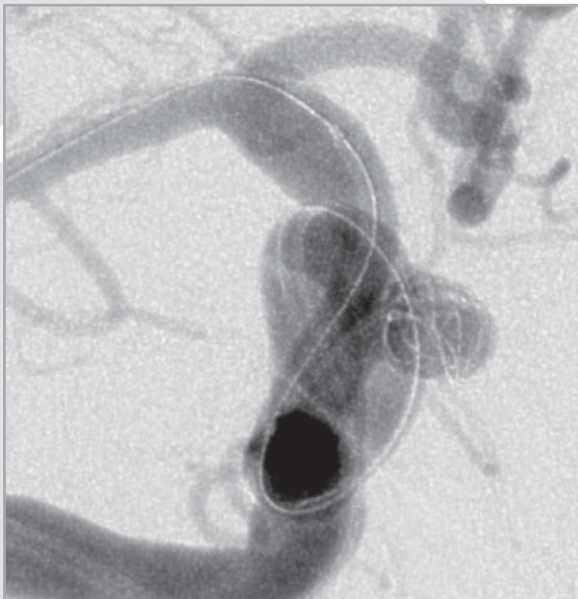
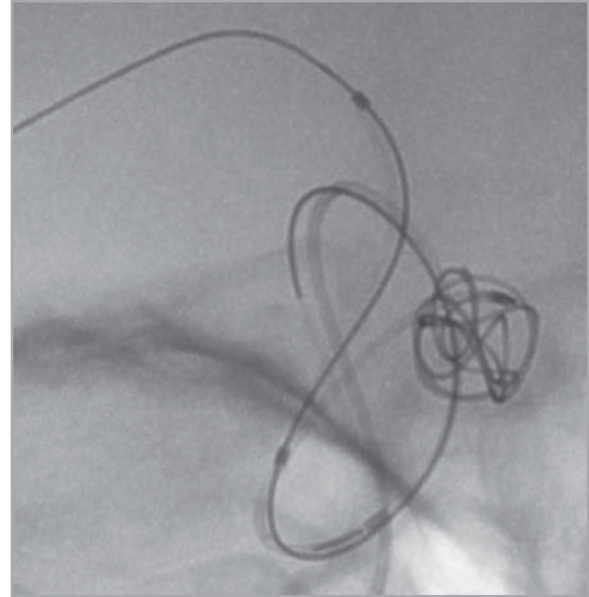
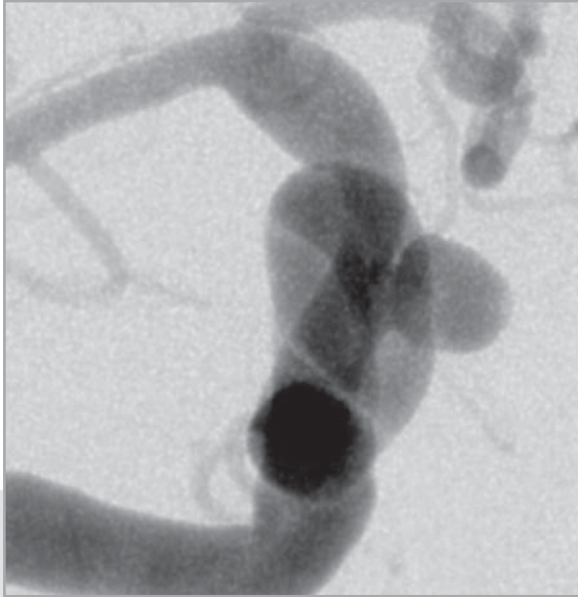


MICRUS® CERECYTE® CASE STUDY

Right Superior Hypophyseal Artery Aneurysm

Michel Mawad, M.D.

Houston, Texas



A 64 year old female presented with a right superior hypophyseal artery aneurysm measuring 6mm with a 3mm neck.

A total of 11 Micrus CERECYTE MICRUSPHERE® Microcoils were used to fill the aneurysm ranging in size from 6mm to 2mm.



micrus®
endovascular

www.micruscorp.com

821 Fox Lane
San Jose, CA 95131
United States
T 408.433.1400
F 408.433.1401

Avenue des Baumettes 7
1020 Renens
Switzerland
T +41.21.631.3434
F +41.21.631.3444

First Floor, Unit 4
Stansted Courtyard
Takeley
Bishop's Stortford
Essex
CM22 6PU
United Kingdom
T +44.800.612.6363
F +44.800.612.8484

MICRUS, MICRUSPHERE, CERECYTE and the M on ball logo are registered trademarks of Micrus Endovascular Corporation.

CAUTION: Federal (U.S.A.) law restricts this device to use by or on the order of a licensed physician.
©2006 Micrus Endovascular Corporation. All rights reserved.