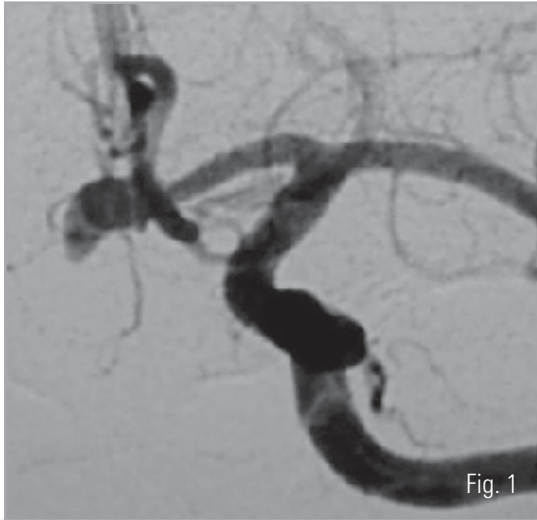


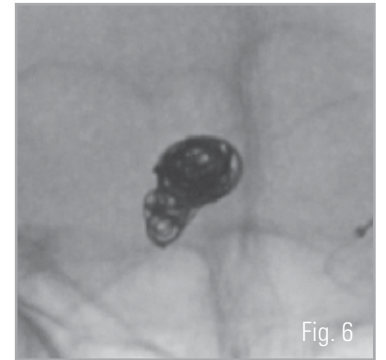
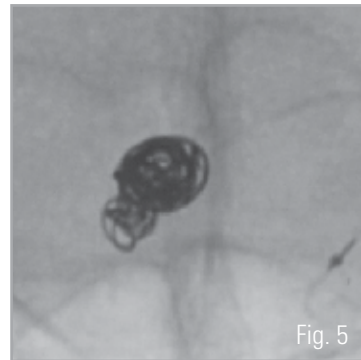
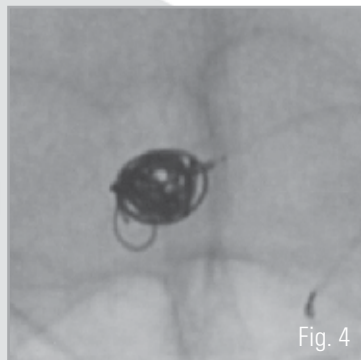
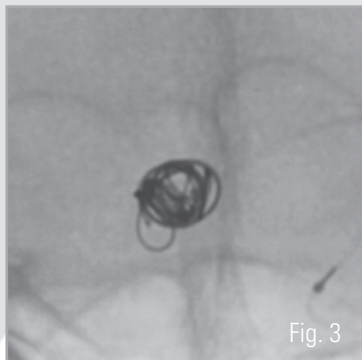
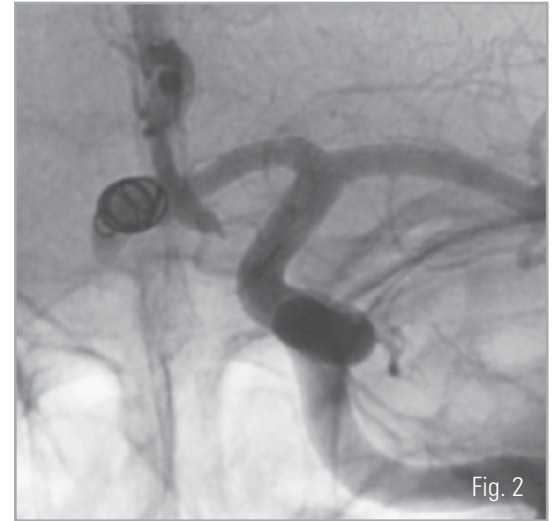
MICRUS® ENDOVASCULAR RUSSIAN DOLL CASE STUDY

Anterior Communicating Artery Aneurysm

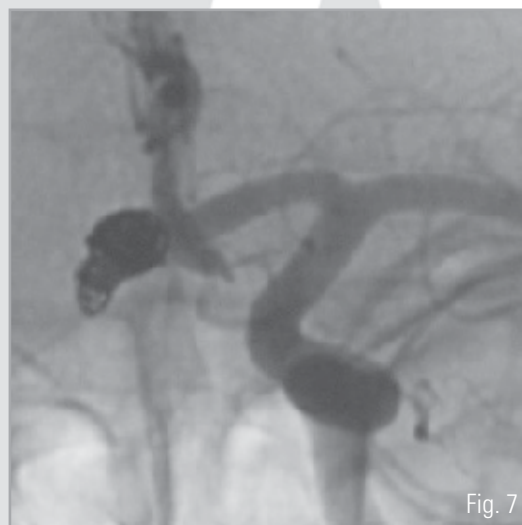Nobuyuki Sakai, M.D., D.M.Sc. • Kobe City General Hospital, Kobe, Japan



A 58 year old female patient presented with an unruptured wide-necked lobulated anterior communicating aneurysm, measuring 4.9mm x 7.2mm x 8.3mm with a 4.6mm neck (Figure 1). A 5mm MICRUSPHERE® Microcoil was placed into the aneurysm as the initial framing coil (Figure 2).



Subsequently, the aneurysm was embolized with four additional MICRUSPHERE® Microcoils. A second 5mm (Figure 3), one 4mm (Figure 4) and two 3mm (Figures 5 and 6), were placed into the aneurysm utilizing a Russian Doll technique.



Finally, two HELIPAQ® Microcoils, a 2mm x 4cm and a 2mm x 2cm (Figure 7), were placed, completing embolization of the aneurysm. No remodeling techniques were required.

MICRUS® ENDOVASCULAR RUSSIAN DOLL CASE STUDY

Anterior Communicating Artery Aneurysm

Nobuyuki Sakai, M.D., D.M.Sc. • Kobe City General Hospital • Kobe, Japan

Micrus Microcoils used:

Two	5mm MICRUSPHERE® Microcoils	SPH100500-20
One	4mm MICRUSPHERE Microcoil	SPH100400-20
Two	3mm MICRUSPHERE Microcoils	SPH100300-20
One	2mm x 4cm HELIPAQ® Microcoil	HEL100204-20
One	2mm x 2cm HELIPAQ Microcoil	HEL100202-20



micrus[®]
endovascular

www.micruscorp.com

821 Fox Lane
San Jose, CA 95131
United States
T 408.433.1400
F 408.433.1401

Avenue des Baumettes 7
1020 Renens
Switzerland
T +41.21.631.3434
F +41.21.631.3444

First Floor, Unit 4
Stansted Courtyard
Takeley
Bishop's Stortford
Essex
CM22 6PU
United Kingdom
T +44.800.612.6363
F +44.800.612.8484

MICRUS, MICRUSPHERE, HELIPAQ and the M on ball logo are registered trademarks of Micrus Endovascular Corporation.

CAUTION: Federal (U.S.A.) law restricts this device to use by or on the order of a licensed physician.
©2006 Micrus Endovascular Corporation. All rights reserved.